

# CLEAR THE AIR

ESTHER KIM, MD

CADENT: METRO ENT AND FACIAL PLASTIC SURGERY

MEDTALKS 2026

PINSTripES, NORTH BETHESDA



# CLEAR THE AIR: SINUSITIS FOR NON-ENT PHYSICIANS


Common sinus  
findings  
misconceptions  
explained

When to refer

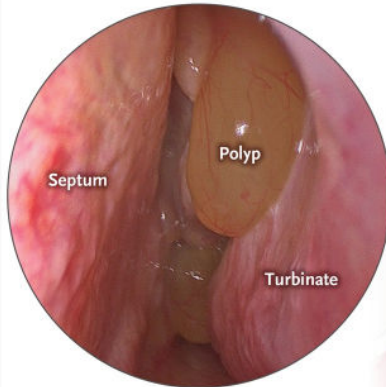
Questions??



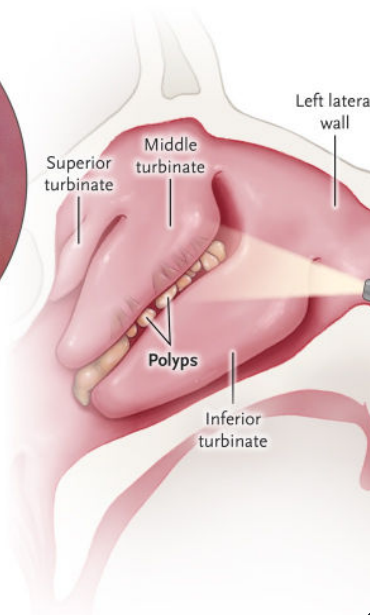
# WHAT ARE NASAL POLYPS?



Rhinoscopic view

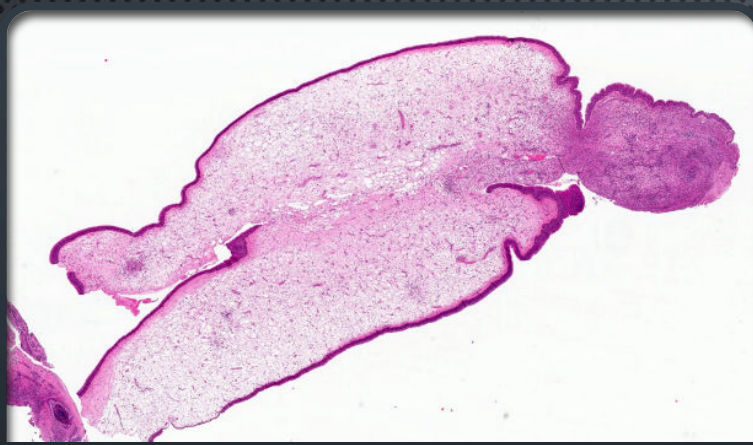


Left Sagittal View



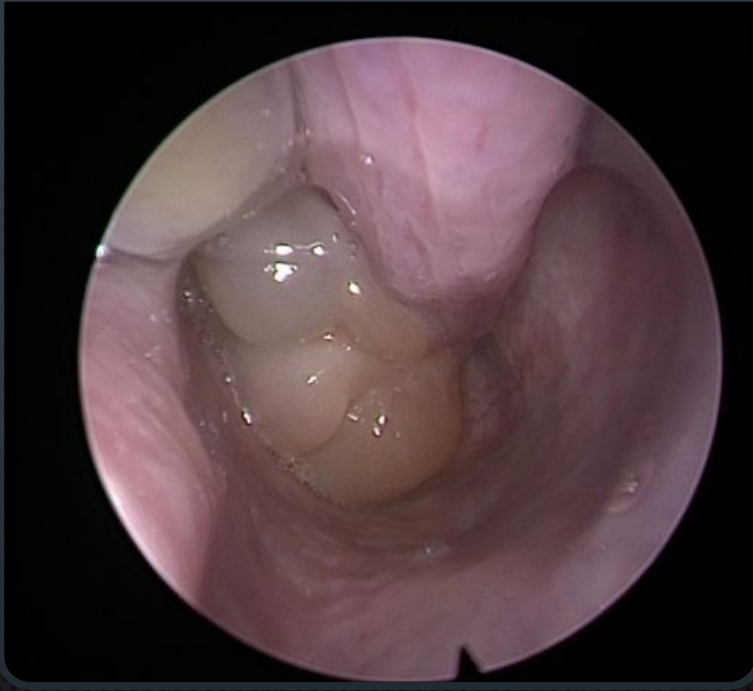
- THEY ARE NOT TURBINATES
- THINK OF A PEEL GREEN GRAPE
- WHEN YOU CAN SEE THEM THEY NEED TO SEE ME!
- I'M STILL HAPPY TO SEE YOUR TURBINATES BUT MOST DON'T NEED TO SEE ME





# NASAL POLYPS

- ABNORMAL INFLAMMATORY TISSUE
- PALE, SOFT, MOBILE
- ASSOCIATED WITH CHRONIC SINUS DISEASE
- NOT NORMAL ANATOMY

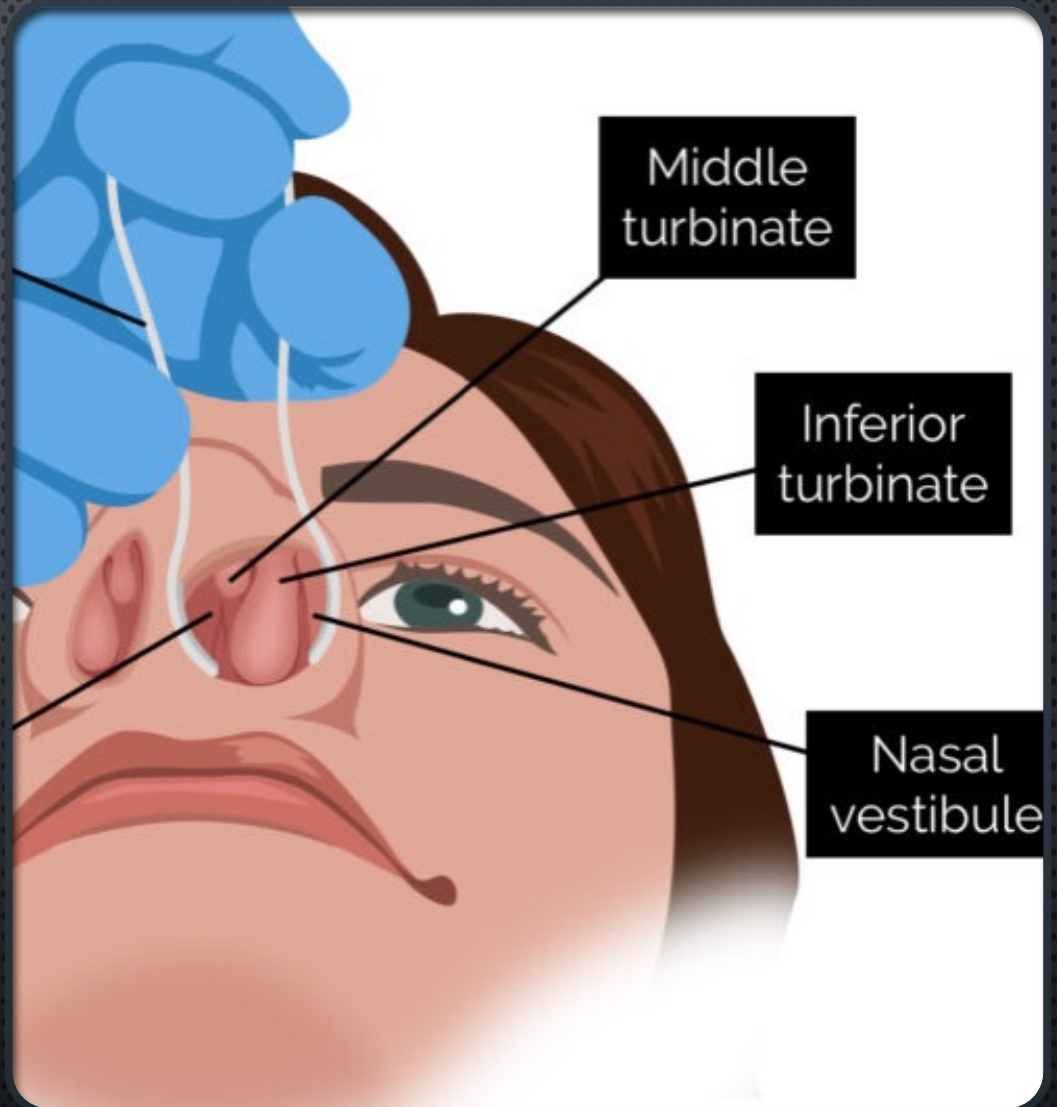




# NORMAL NASAL ANATOMY

- Warms & humidifies air

- Can appear large when inflamed



# WHAT SINUSITIS IS (AND IS NOT)



INFLAMMATION  
OF SINUS  
MUCOSA



MAY BE VIRAL,  
ALLERGIC, OR  
INFLAMMATORY



INFECTION IS  
ONLY ONE  
CAUSE



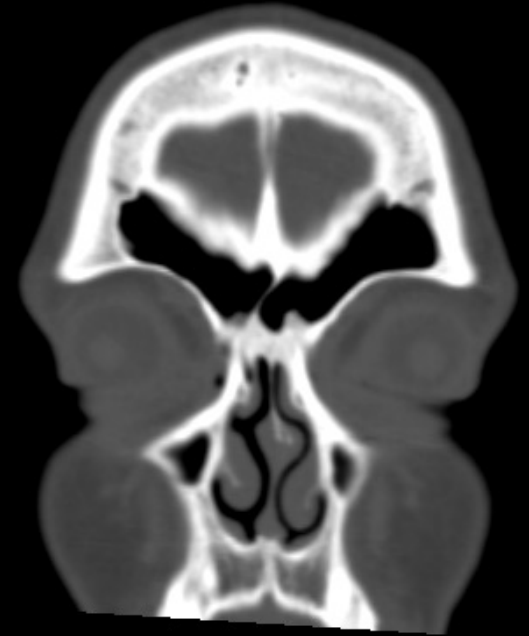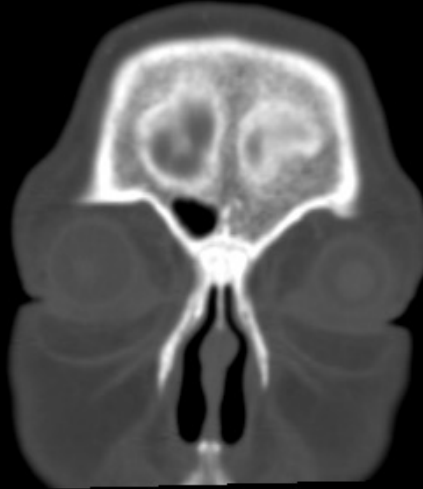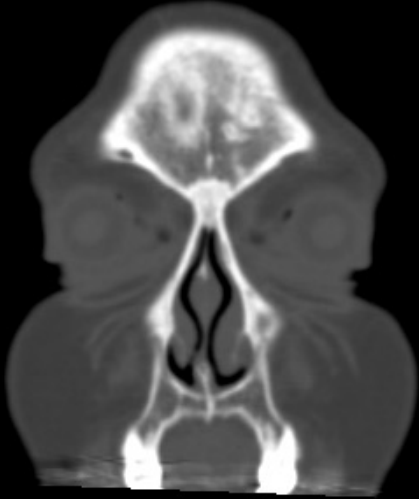SYMPTOMS ≠  
IMAGING  
FINDINGS





# I HAVE A SINUS HEADACHE

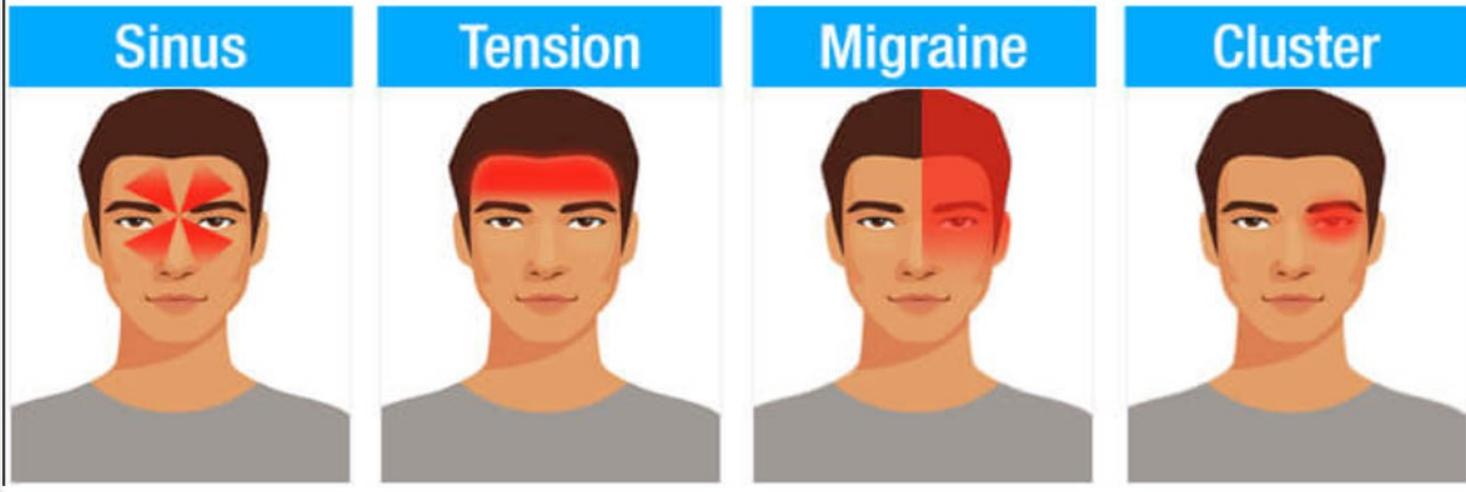
- OR MAYBE YOU DON'T....
- WHEN DOES IT OCCUR?
- WHERE IS THE HEADACHE?
- VERTEX? OCCIPUT? FRONTAL BAND?
- UNILATERAL?
- EYE SYMPTOMS?
- NAUSEA?
- SENSITIVITY TO LIGHT?



CAN THIS BE A SINUS  
HEADACHE?



# Headache Type



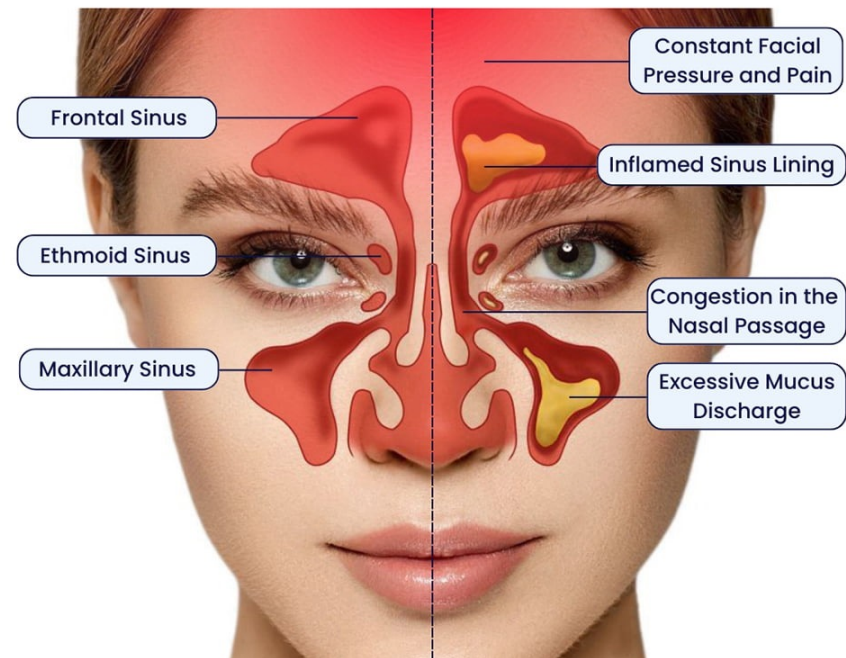
TYPES OF HEADACHES

# I'M DRAINING AND I NEED AN ANTIBIOTIC

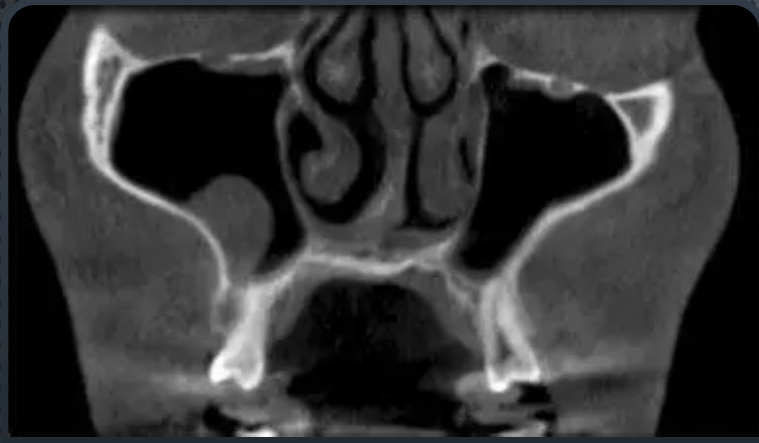
- NO, YOU NEED AN EVALUATION
- CLEAR? COLORED?
- PND?
- MORE THAN 10 DAYS AFTER A URI?
- IRRIGATING?

Healthy Sinus

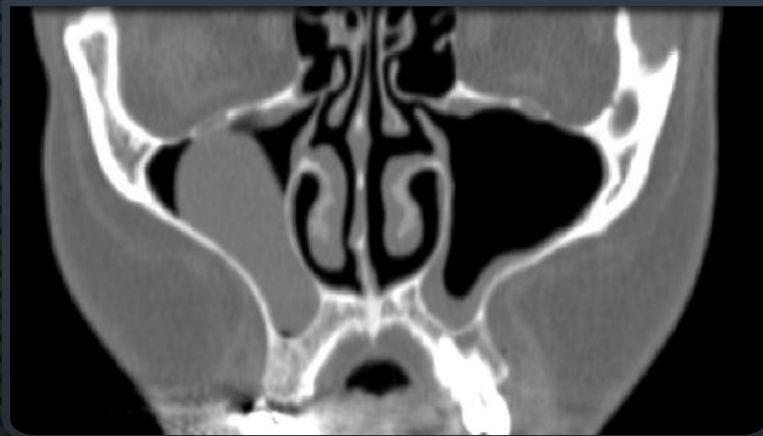Sinusitis







## DO I HAVE A SINUS TUMOR?



- NO, YOU HAVE A MUCOUS RETENTION CYST (~30% OF YOU DO)
- THINK OF IT AS THE EQUIVALENT OF A SINUS PIMPLE
- IF THEY BLOCK, THEY MAY NEED TO BE DRAINED BUT MAINLY LIVE IN THE FLOOR OF THE MAXILLARY SINUS

## WHY THIS MATTERS

---

Turbinate  
hypertrophy  $\neq$  polyps

---

Swelling  $\neq$  bacterial  
infection

---

CT abnormalities may  
be incidental

---

Understanding the  
timing can help treat



# WHEN TO REFER TO ENT

Persistent  
symptoms > 12  
weeks

Recurrent  
symptoms despite  
a good round of  
antibiotics

Concern for nasal  
polyps

Unilateral  
symptoms or red  
flags eye changes,  
bleeding

Abnormal imaging

# QUESTIONS??

- ESTHER KIM, MD
- METRO ENT AND FACIAL PLASTIC SURGERY
- ROCKVILLE, MD
- 301-315-0003



DR. KIM'S  
CONTACT INFO:  
(Personal cell phone)

